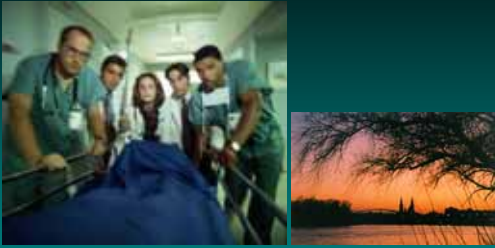

CAOS or Chaos?



Prof. Endre Varga MD. Phd. (med)
University of Szeged, Department of Trauma Surgery

CAOS

Computer Assisted Orthopedic Surgery



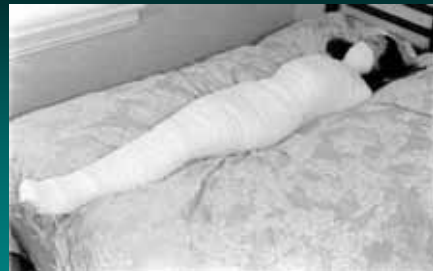Endre Varga MD. Phd. (med) habil
University of Szeged, Department of Trauma Surgery

CAOS

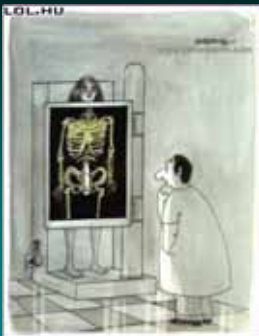Surgical planning



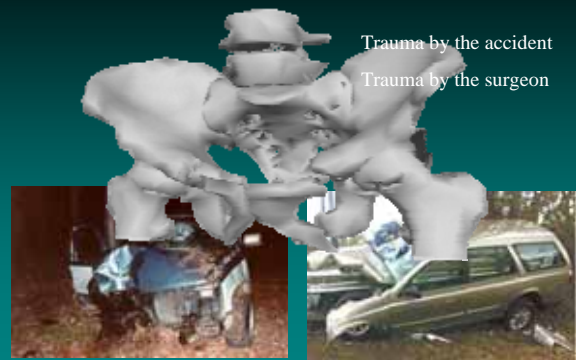Surgical planning Plaster of Paris



Surgical planning We are able to see almost everything...



Serious multiple injuries

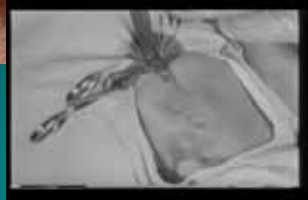

Trauma by the accident
Trauma by the surgeon

Serious multiple injuries

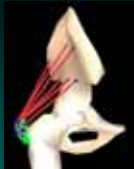


Trauma by the accident
Trauma by the surgeon




Computer-Assisted Orthopaedic Surgery (C.A.O.S.)

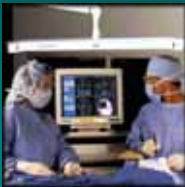Computer-based technologies



3D Visualization



Preoperative Planning



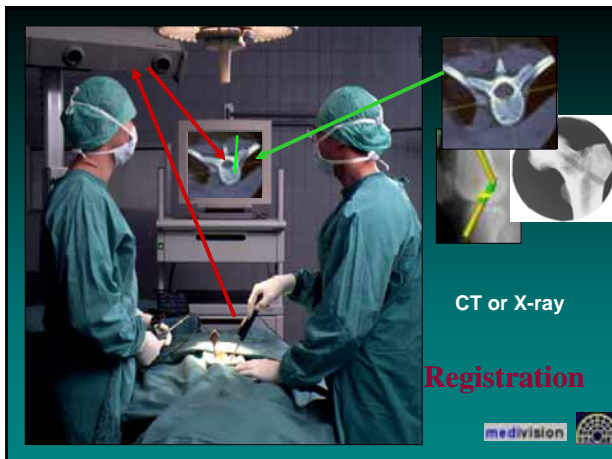
Intraoperative Navigation



Robotics

Computerized fluoroscopic navigation

Registration -
fluoroscopic rather than CT/MRI



CT or X-ray

Registration

medivision


Navigation system

Localization
Camera Array



Image Processing
Computer System

Calibration target

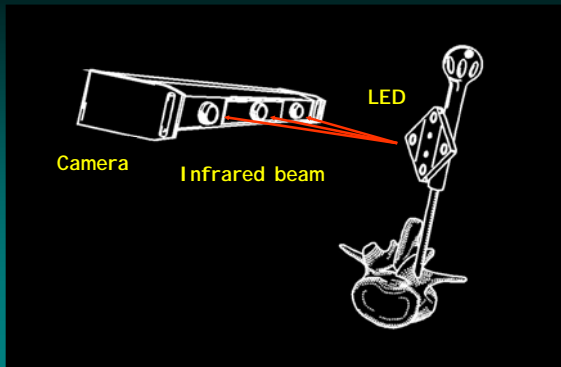


- LED tracking
Enables precise localization of C-arm.
- Radiation sensors
Allows automatic image acquisition.
- Calibration grid
Appear in images and are automatically erased.

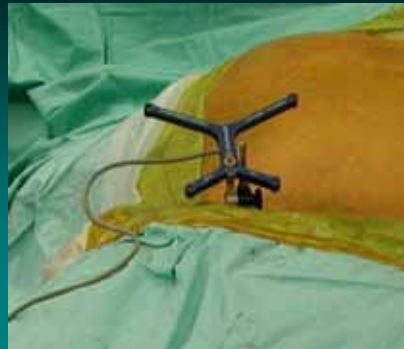Tracked instruments



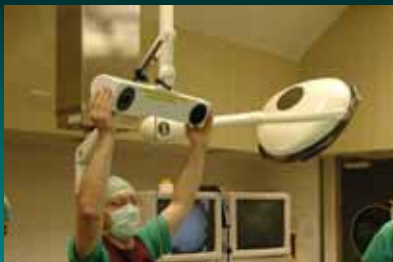Optical tracking principle



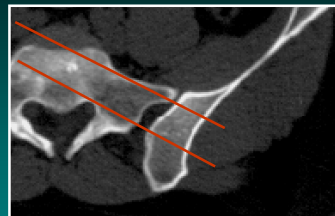Attach reference frame



Aim camera

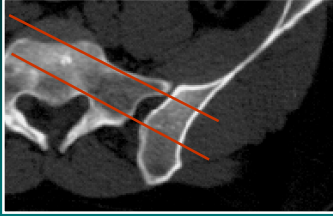

“Safe Zone”



Gay SB et al:

Percutaneous fixation using CT guidance.

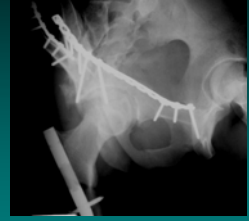


Percutaneous screw fixation of acetabular fractures with CT guidance

AJR 1992;158:822-819

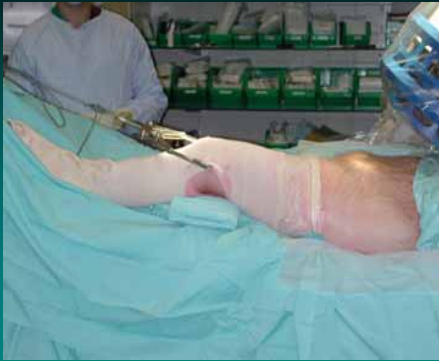Fluoroscopy in pelvic & acetabular fractures:

Kahler DM:
1 minute of fluoroscopy time about the pelvis
=40 mSv of radiation
=250 chest radiographs

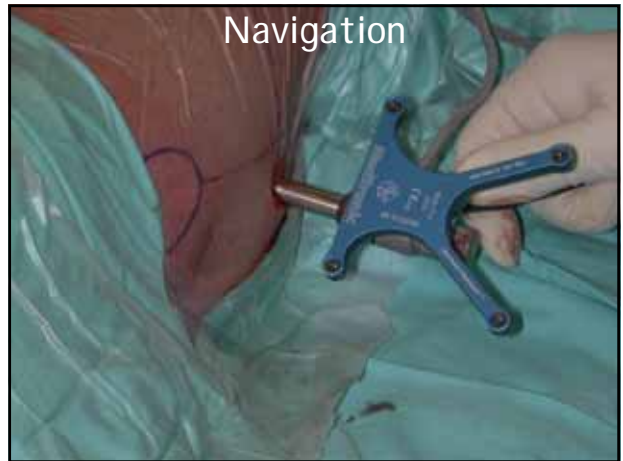


Virtual fluoroscopy: a tool for decreasing radiation exposure during femoral intramedullary nailing.
CAOS USA, Pittsburgh, PA, July 2001. p 167-170.

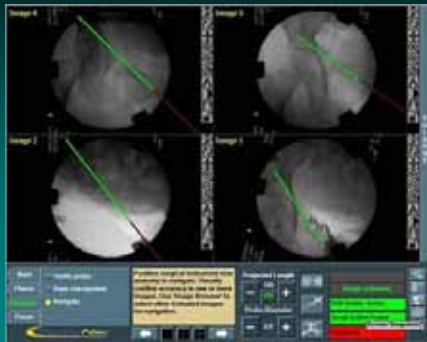
Acquire several images



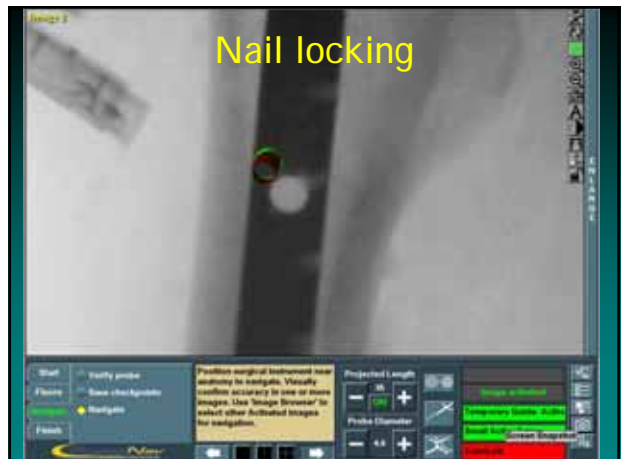Navigation

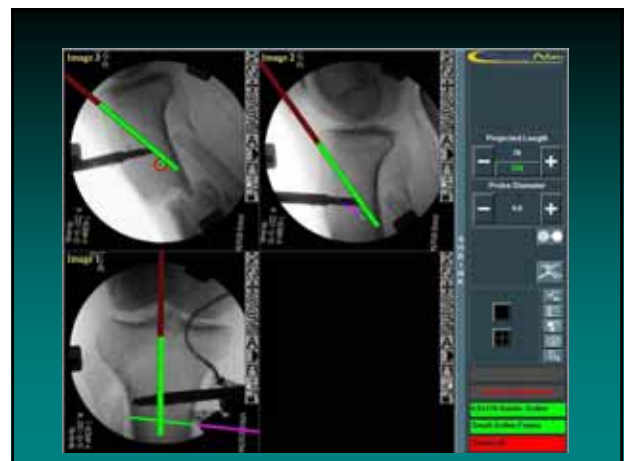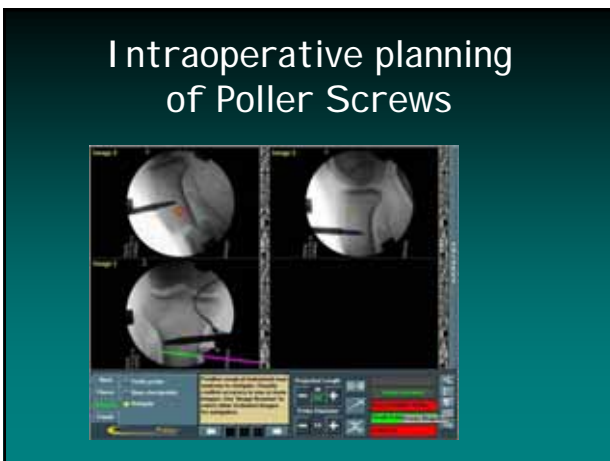
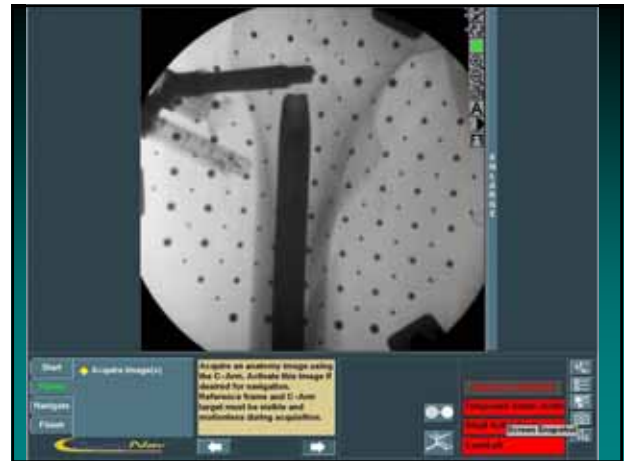

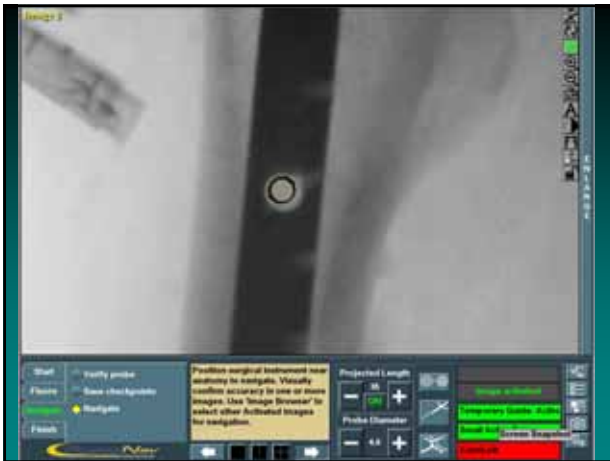
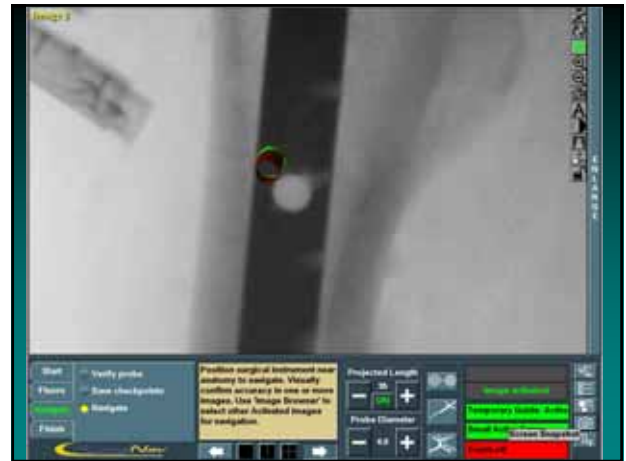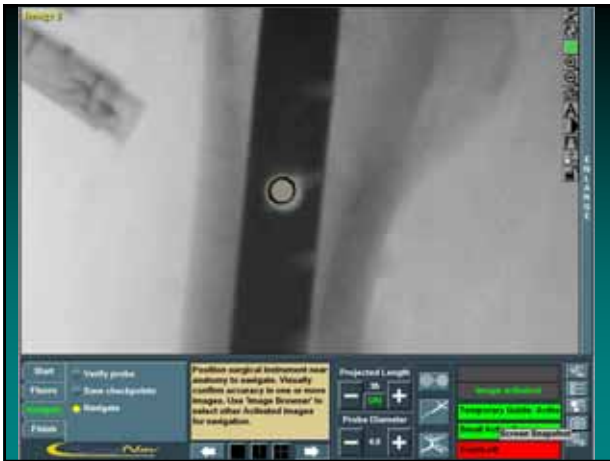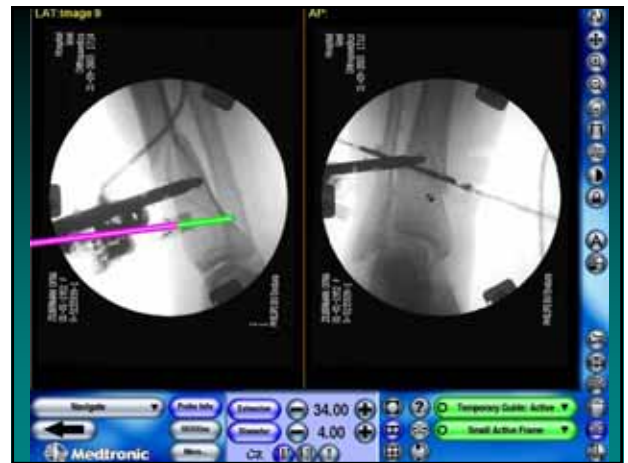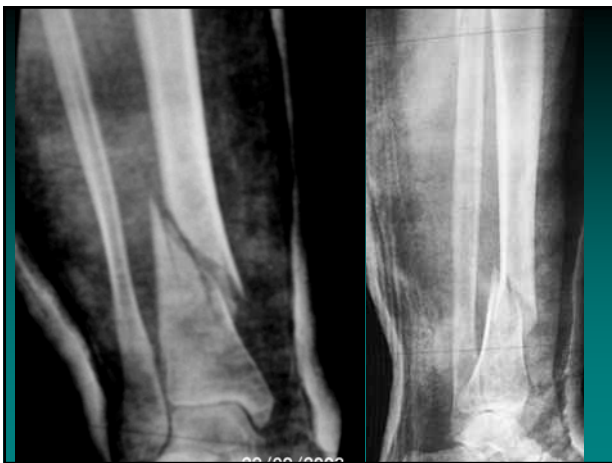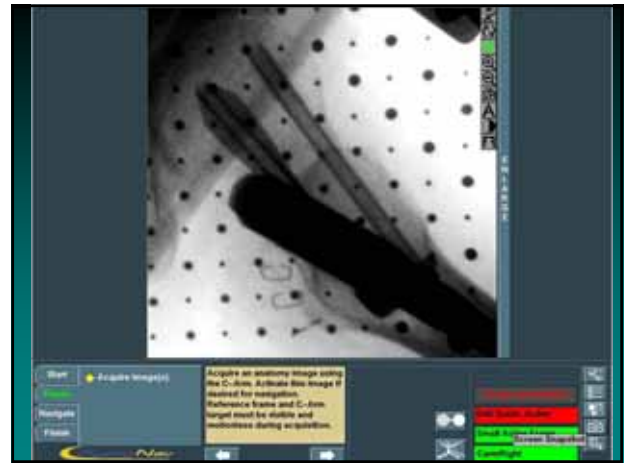
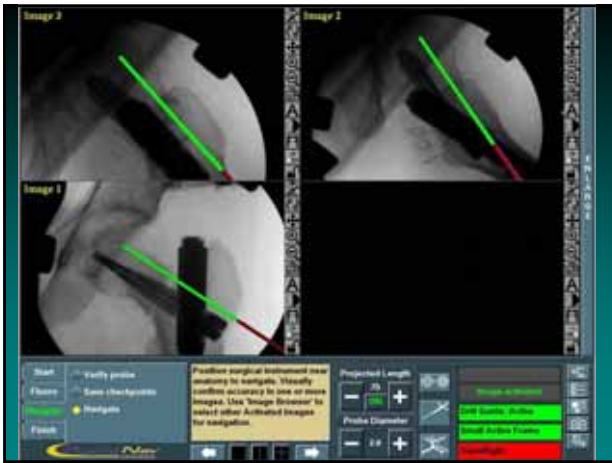
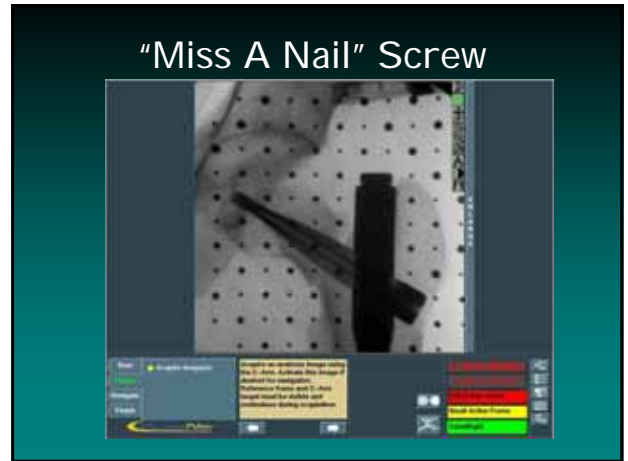
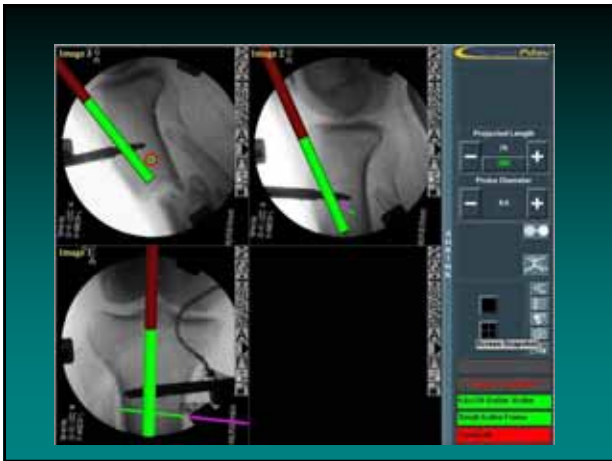Multi-image navigation

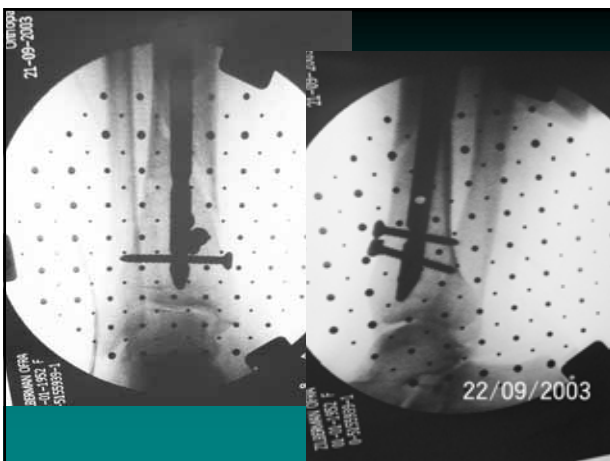
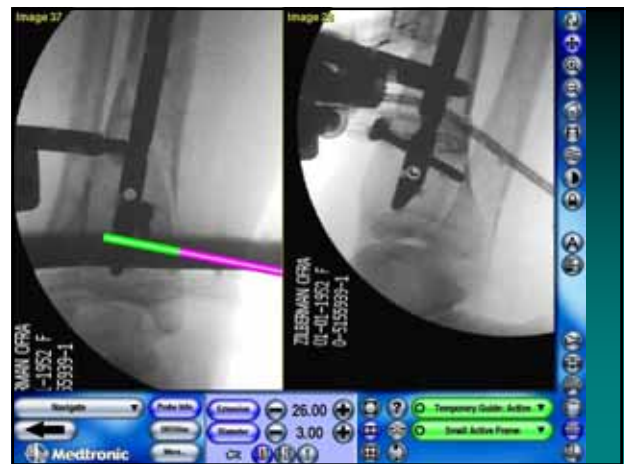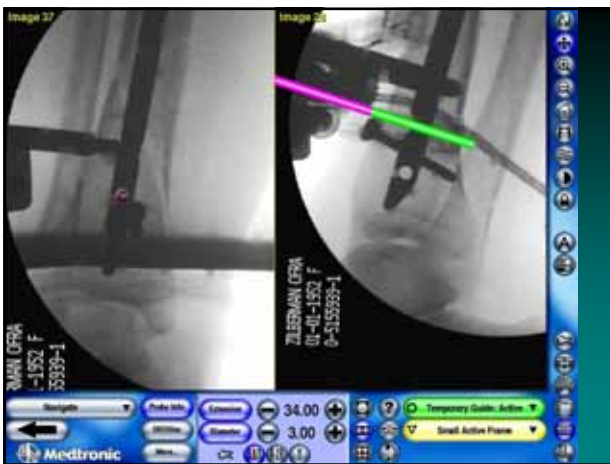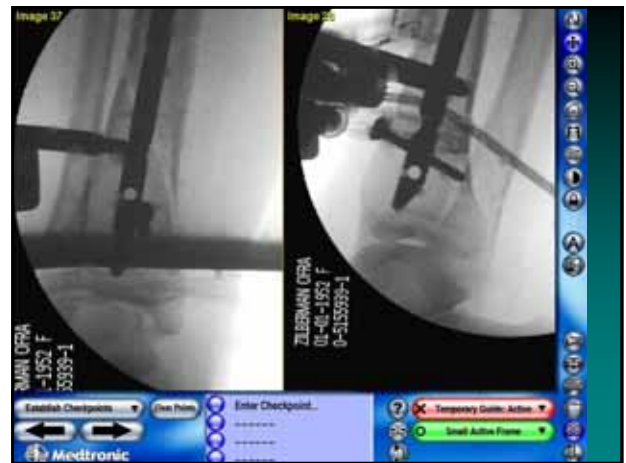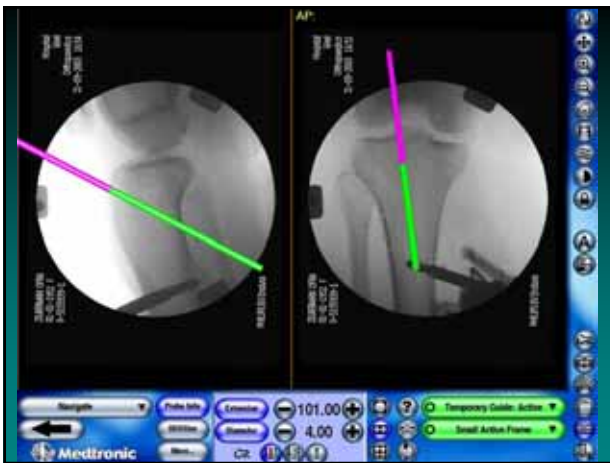


Nail locking









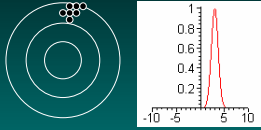
1st Generation Navigation

tracking +
registration +
visualization

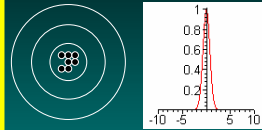
- Accurate
- Simple
- Reduce time and radiation
- Simultaneous multi-image navigation
- Advanced information

What kind of accuracy?

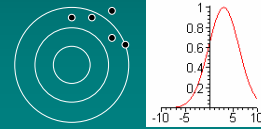
large bias + high precision



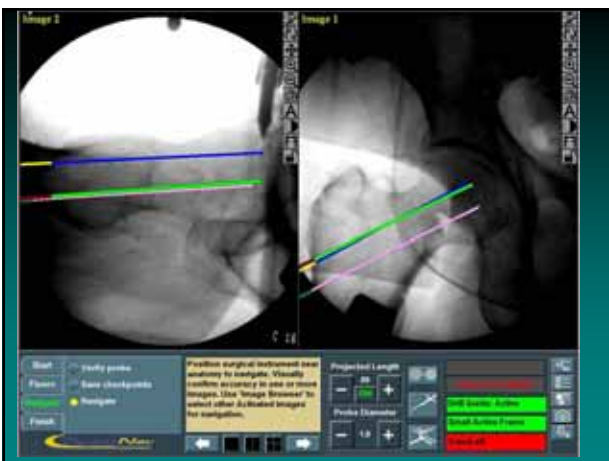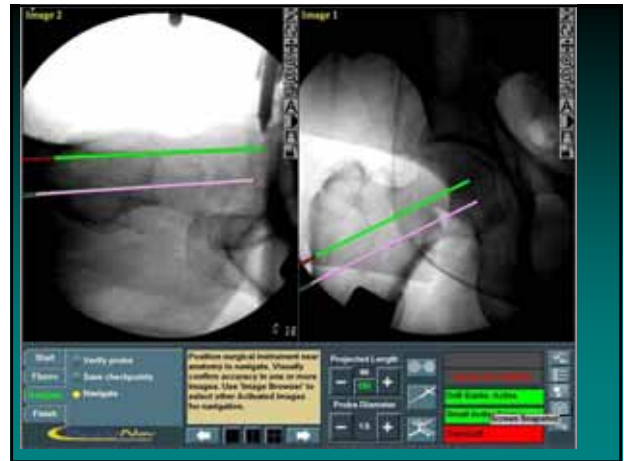
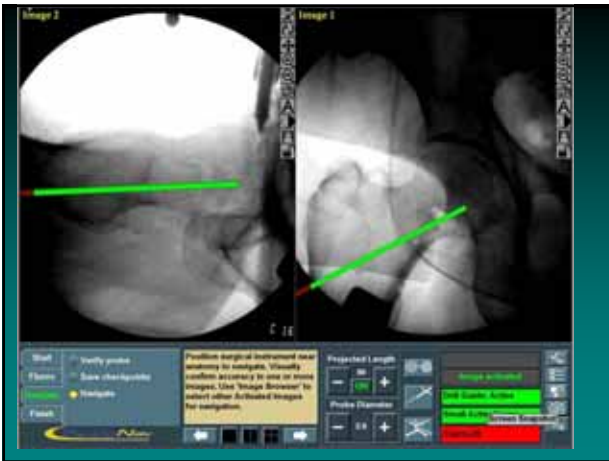
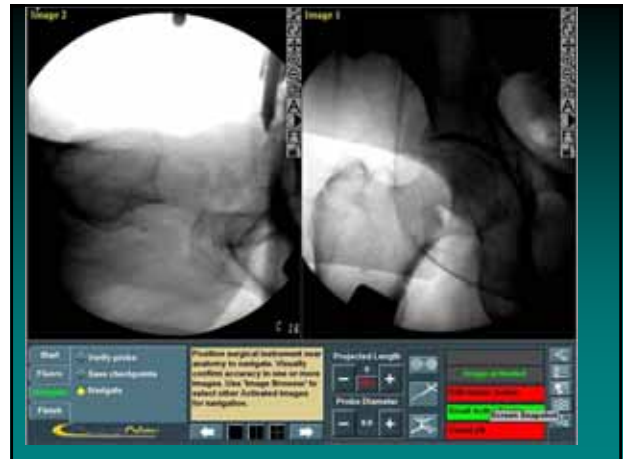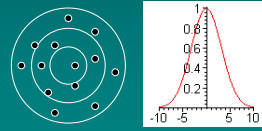
no bias + high precision



large bias + low precision

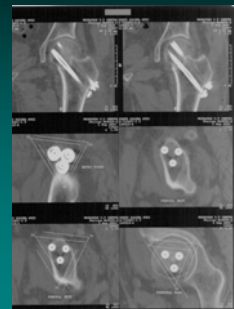


No bias + low precision



THE ROLE OF COMPUTERIZED NAVIGATION IN FIXATING FEMORAL NECK FRACTURES

Ben-David D, Mosheiff R, Weil Y, Peyser A, Liebergall M



THE ROLE OF COMPUTERIZED NAVIGATION IN FIXATING
FEMORAL NECK FRACTURES

Ben-David D, Mosheiff R, Weil Y, Peyser A, Liebergall M

Significantly better screw scattering
Significantly better screw parallelism

Standard Multiplanar Fluoroscopy Versus
a Fluoroscopically Based Navigation System for the
Percutaneous Insertion of Iliosacral Screws
A Cadaver Model

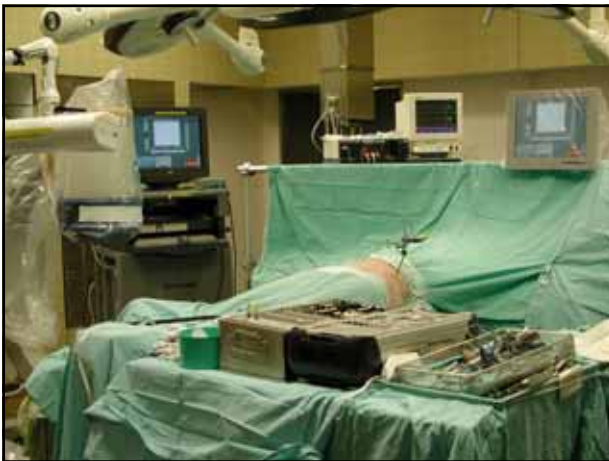Cory Collinge, MD,* David Coons, DO,† Paul Tornetta, MD,‡ and John Aschenbrenner, PhD§

Average fluoroscopy time:

StdFluoro - 26 seconds
VirtualFluoro - 6 seconds

(P < 0.01)

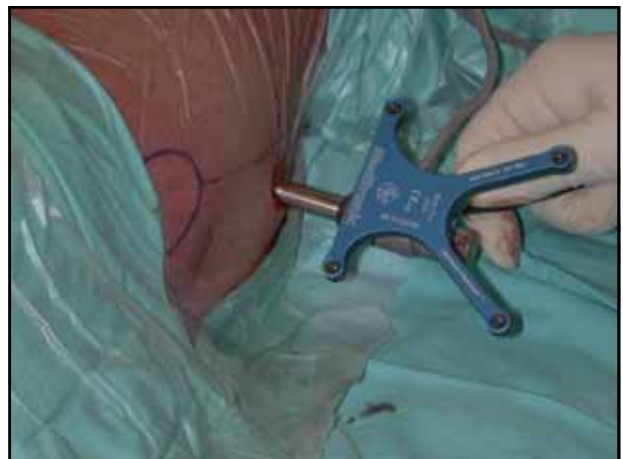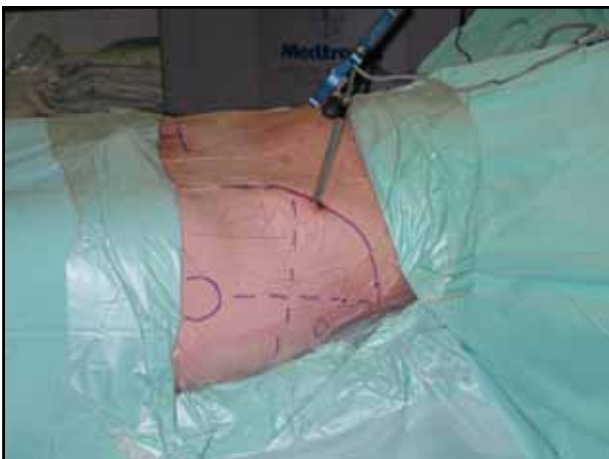
J Orthop Trauma • Volume 19, Number 4, April 2005

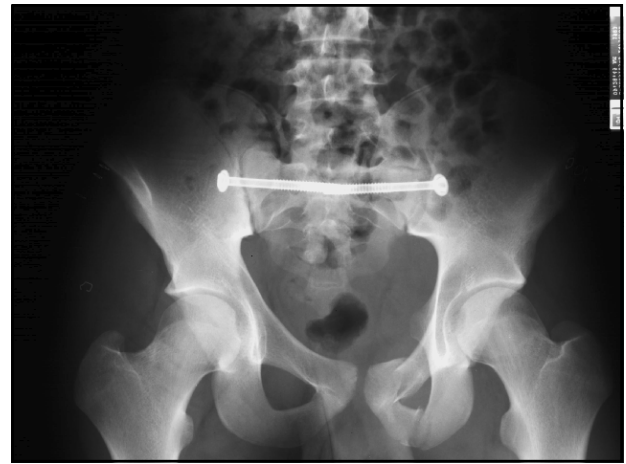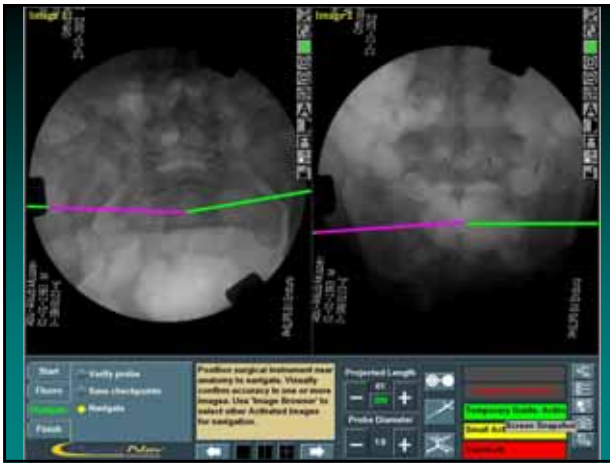
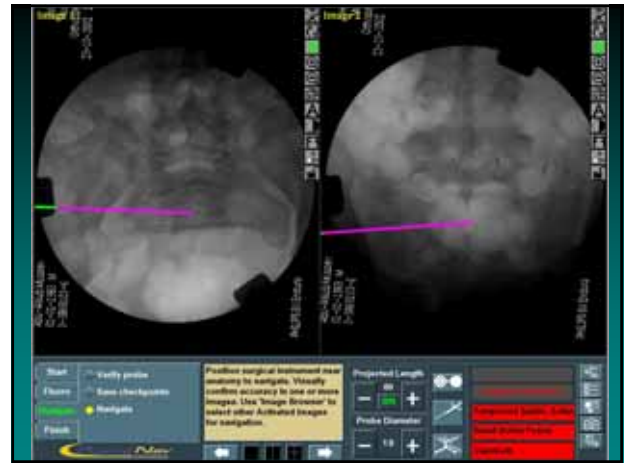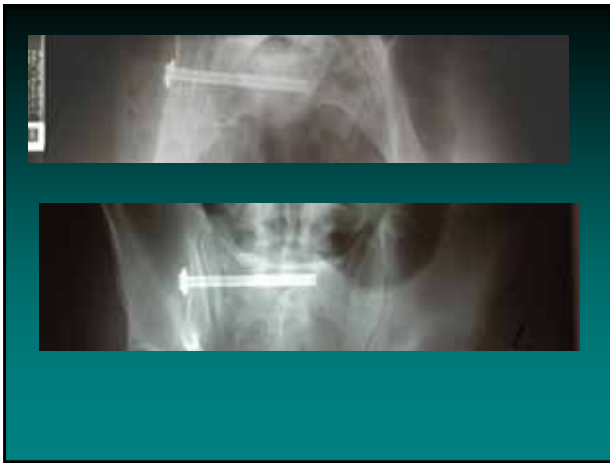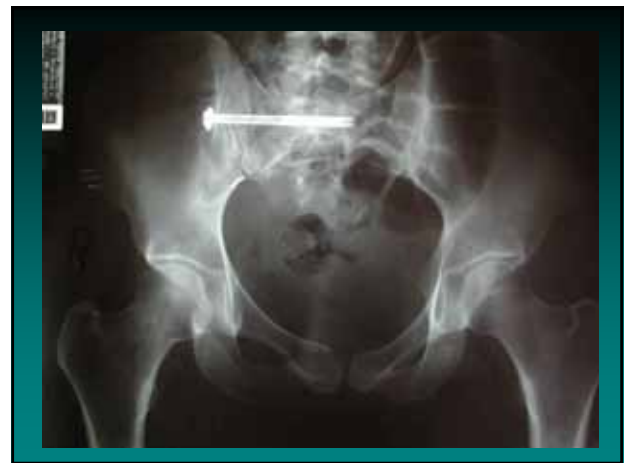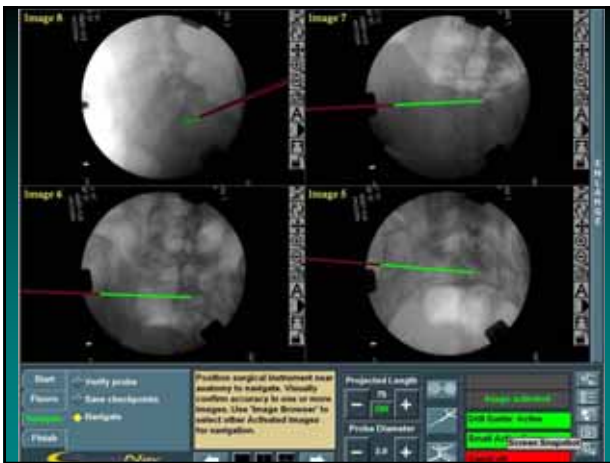


Acquired images:

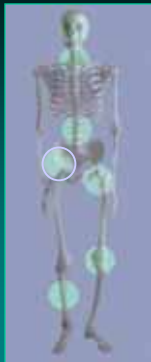Screw type: _____ No of images: _____

- Sacroiliac 2-3
- Ramus-Pubis 3-4
- Transverse/Iliac 2-3
- Posterior-Column 2-3

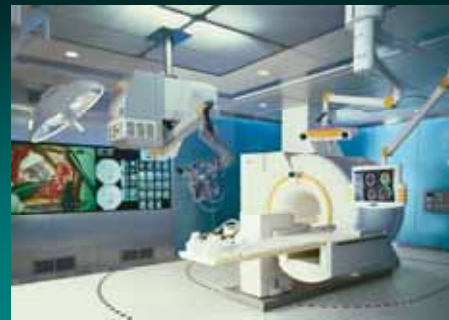



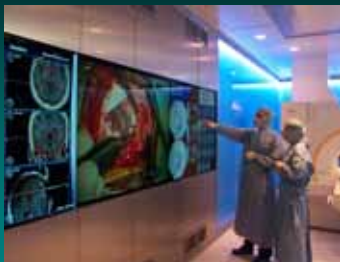Regions



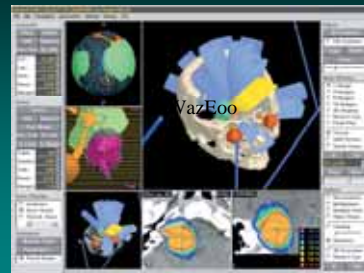BrainSuite



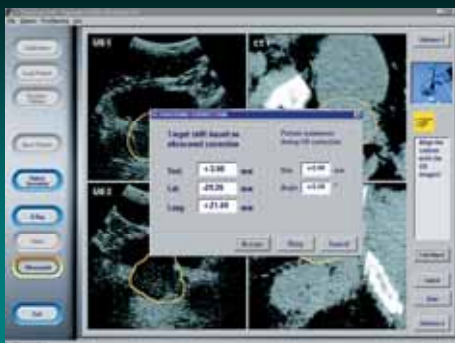
BrainSuite



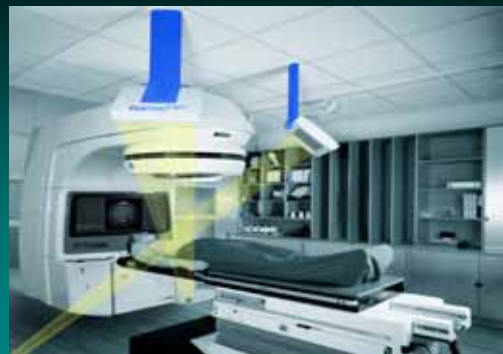
Tumor irradiation planning-radiosurgery



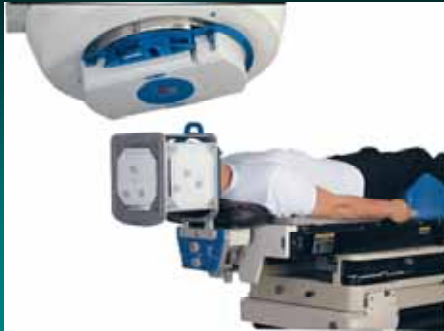Tumor irradiation planning-radiosurgery



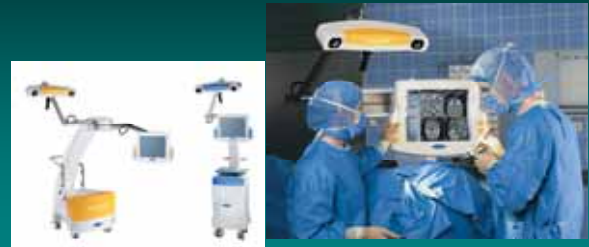Tumor irradiation planning-radiosurgery



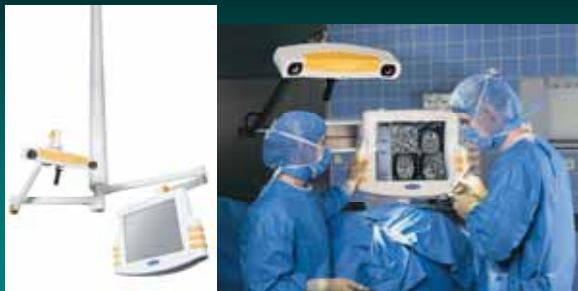Tumor irradiation planning-radiosurgery



Devices



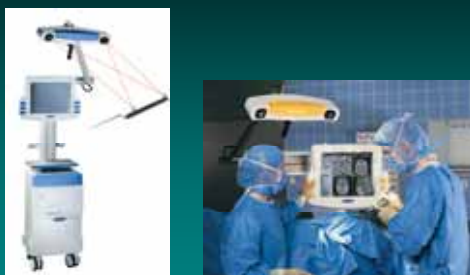Ceiling



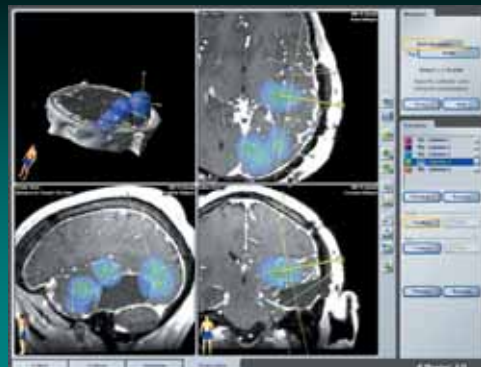
Colibri



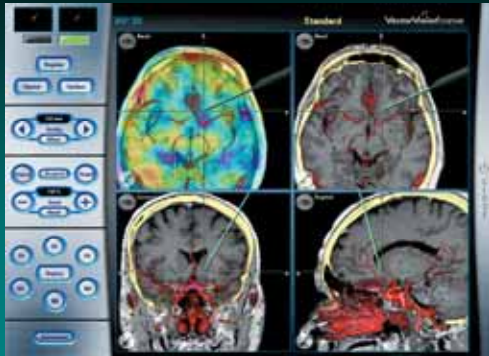registration



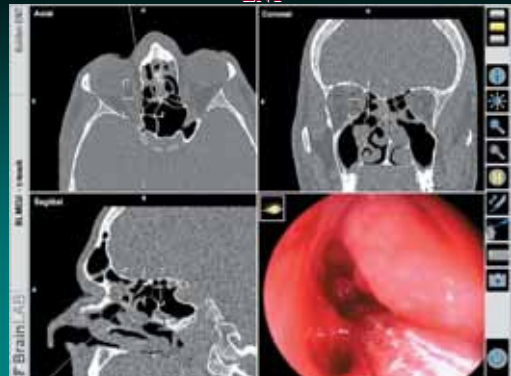
Tumor irradiation planning-radiosurgery



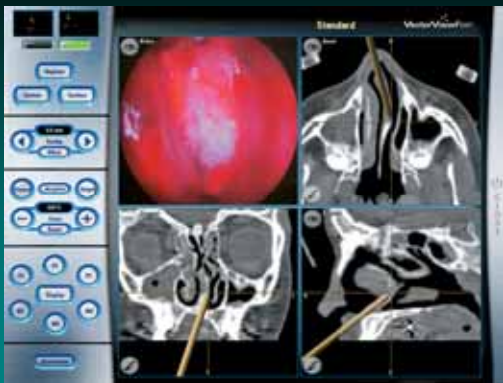
Cranial Image Composer



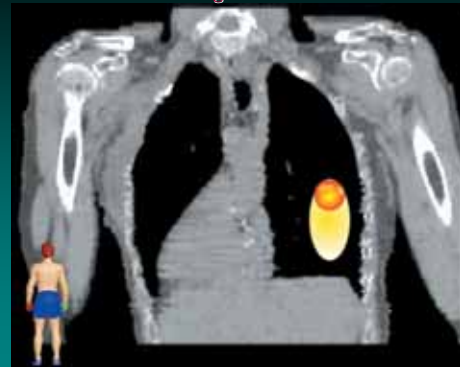
ENT



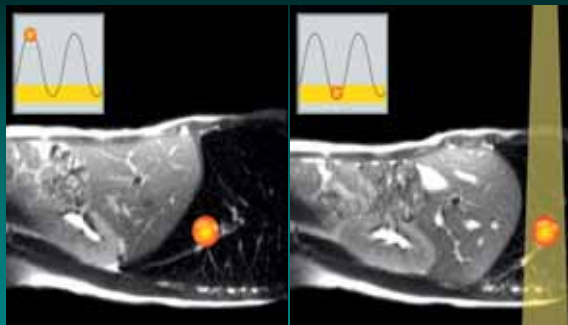
ENT



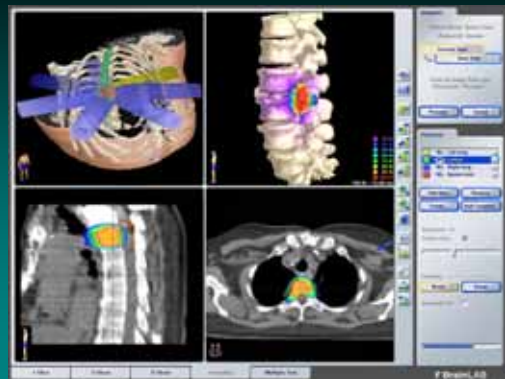Lung tumor



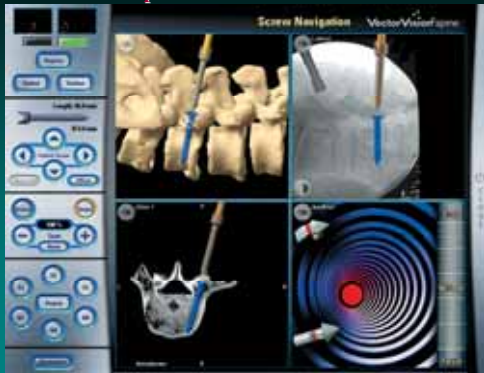Lung tumor



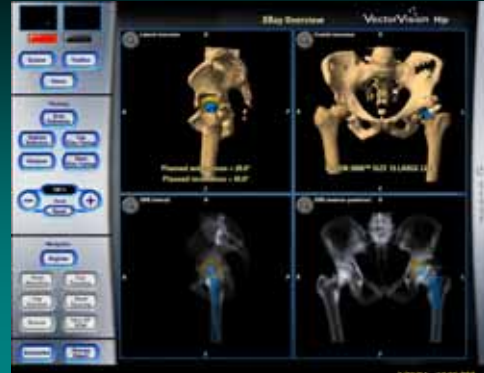Spine tumor



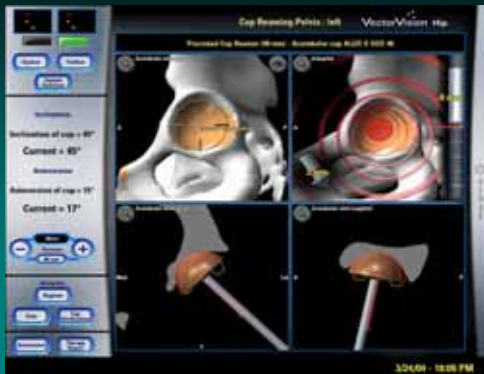Spine-Pedunculus screw



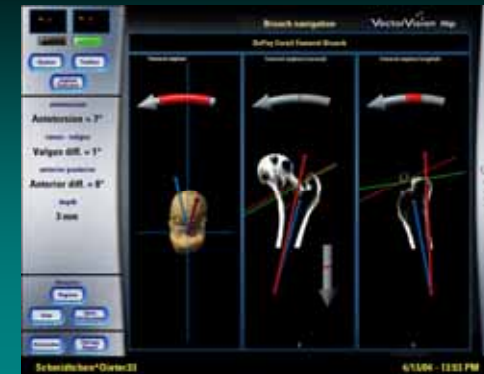Pelvis - Acetabulum - THP



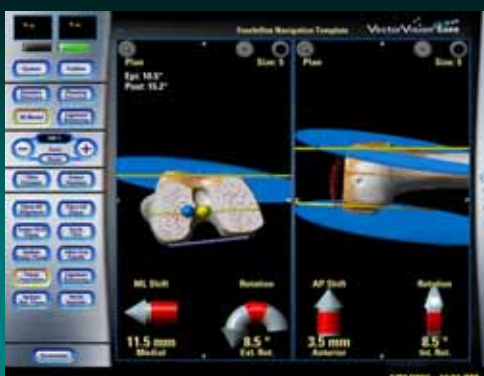Pelvis - Acetabulum - THP



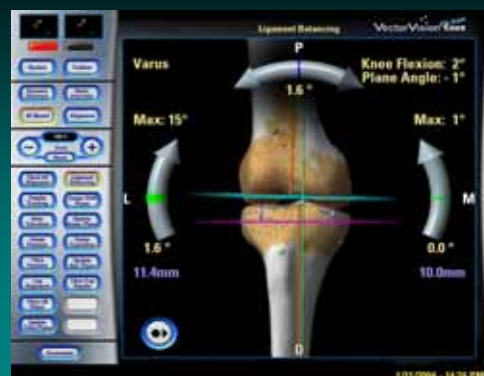Pelvis - Acetabulum - THP



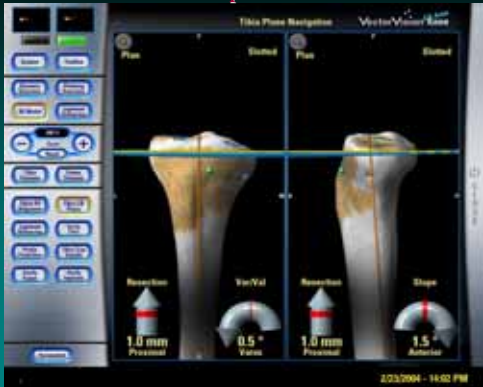Knee prosthesis



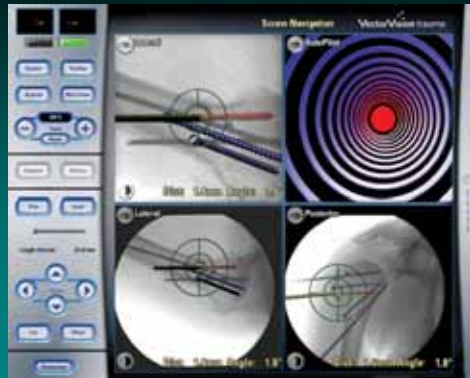Knee prosthesis



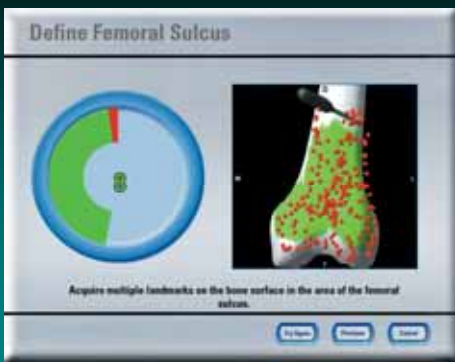
Knee prosthesis



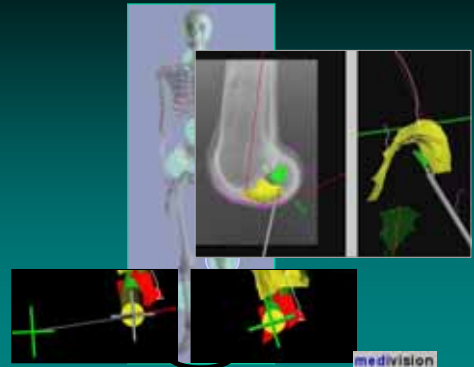
Percutan screw placement into the humeral head



Multiple landmarks/ ACL plasty



Multiple landmarks/ ACL plasty

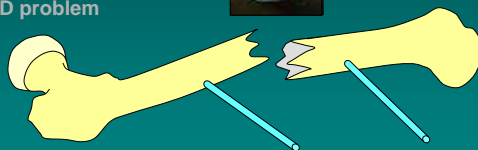

Femoral nailing

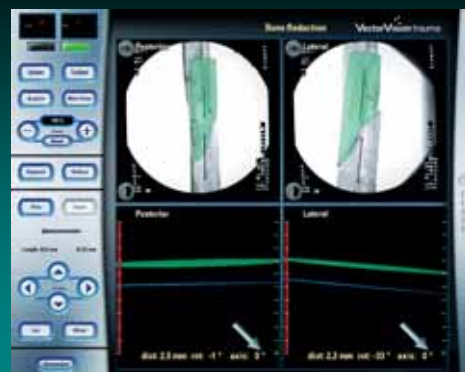Reduction

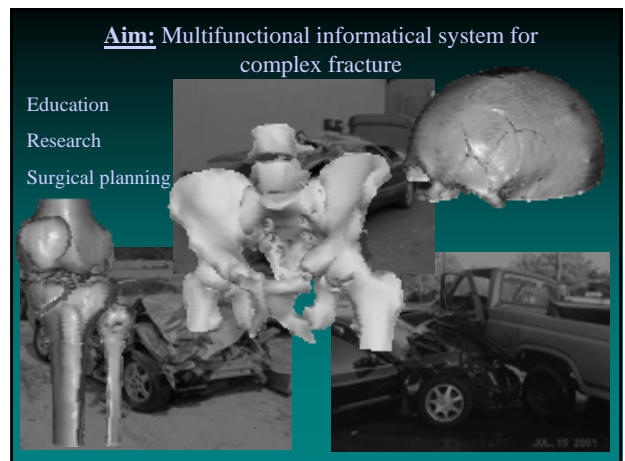
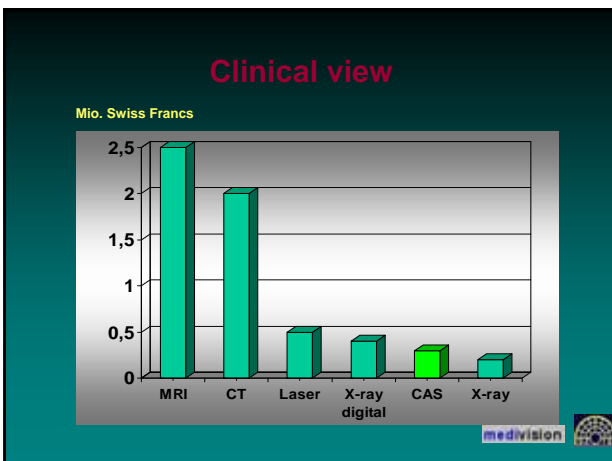
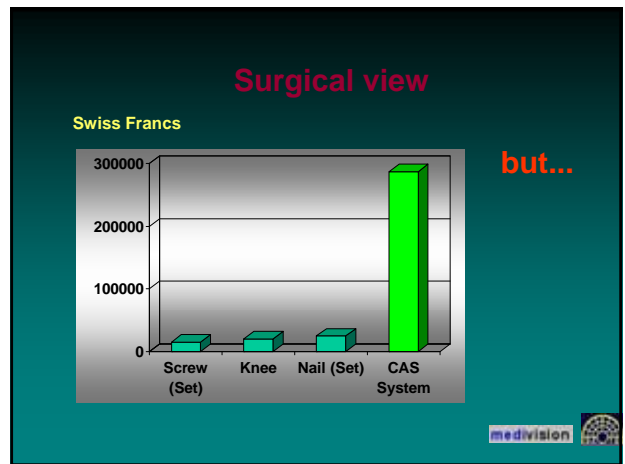

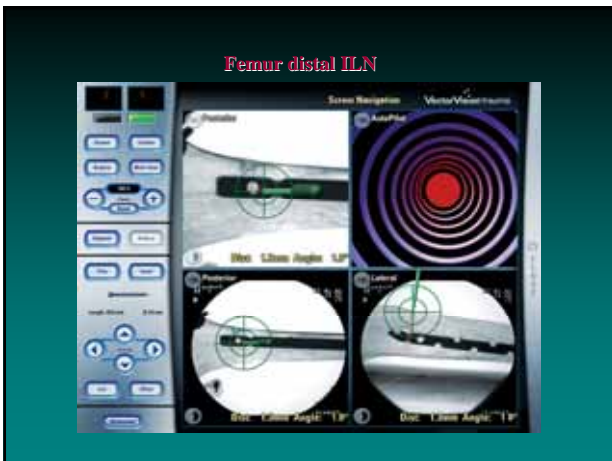
High dose irradiation

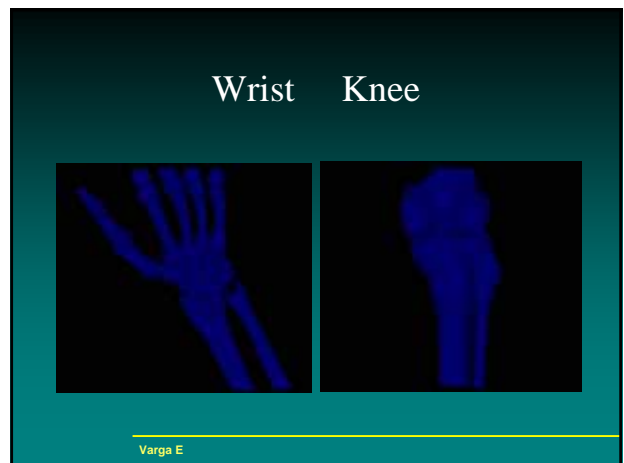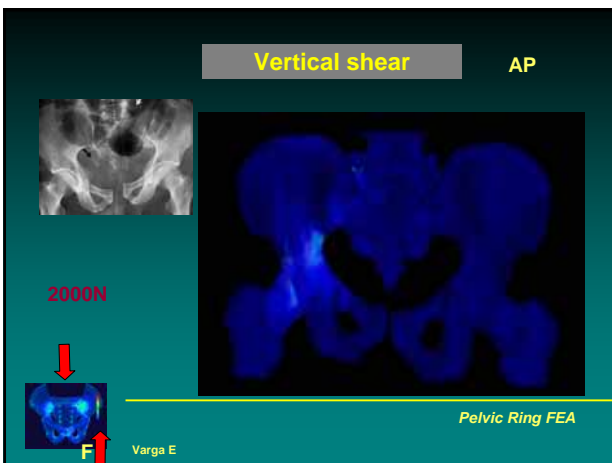
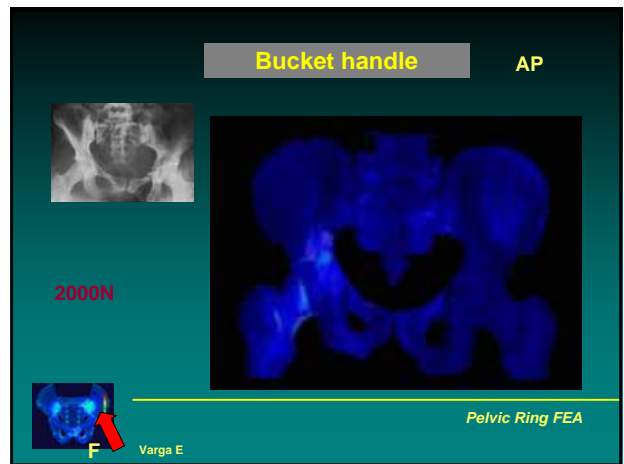
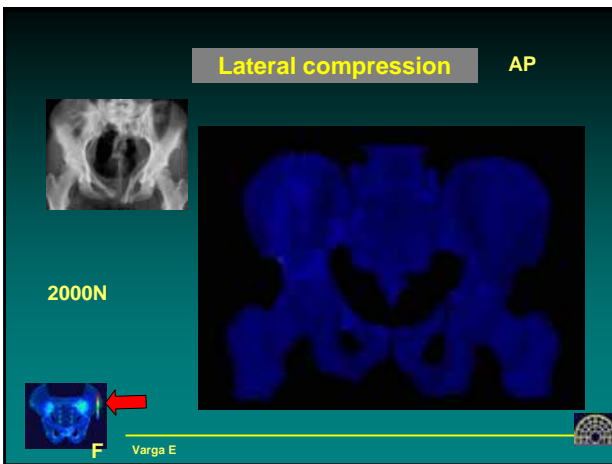
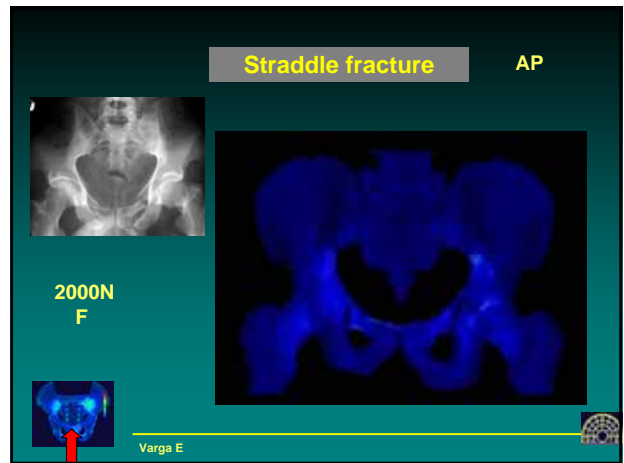
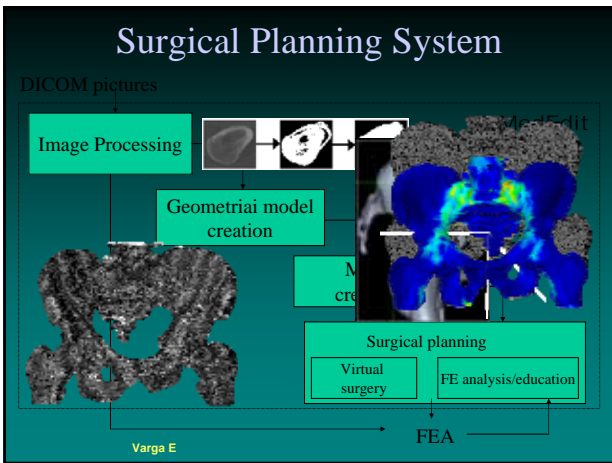
3D problem



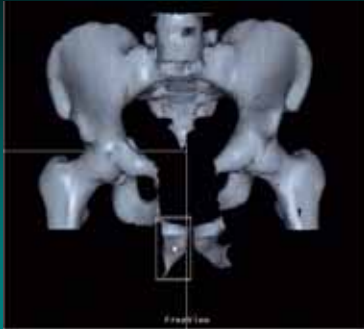
Reduction







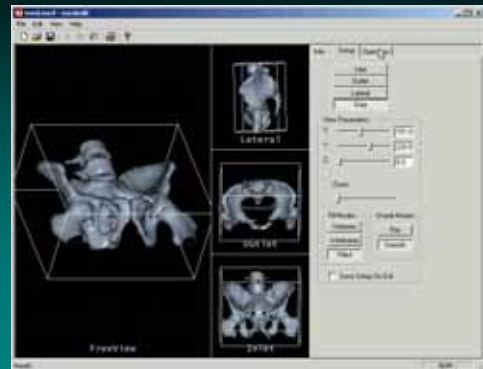
Surgical planning



"Bone fitting"

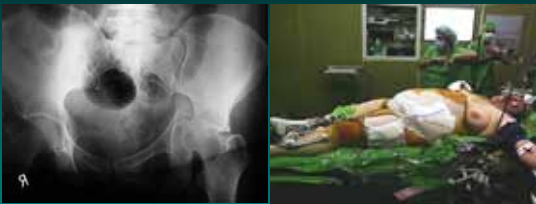Varga E

Surgical planning



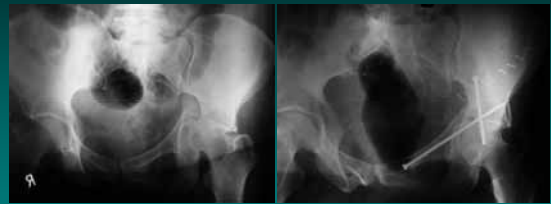Minimal invasive techniques

47Y /female /143 kg



Patient #1

E.J-né, 47 éves, 143 kg



Advantages

- Minimal invasive
- Accuracy
- Radiation ↓
- Complications ↓

Team work

